# Posttraumatic Subfibular Ossicle Formation in Children: Experience in a Single Primary Care Unit

*Dong Yeon Lee, MD, PhD,* Doo Jae Lee, MD,* Dong Han Kim, MD,† Hyuck Soo Shin, MD,* and Whan Ik Jung, MD**

**Background:** Although subfibular ossicles have been linked to various clinical problems, whether its origin is congenital or traumatic remains unclear. The objectives of this study were to determine the incidence of subfibular ossicle formation after ankle inversion in children.

**Methods:** Among 896 pediatric patients who visited a single primary care unit after foot and ankle trauma, 593 patients sustaining ankle inversion injury were included in this study. For each pediatric patient, physical examination and radiographic examination were performed. The incidence of subfibular ossicle was evaluated based on initial radiographic examination. To analyze the incidence of unprecedented subfibular ossicle formation after ankle inversion injury, radiographs of 188 patients who were followed up for >6 months were evaluated according to the grade of initial injury.

**Results:** At initial visit, 1.0% of examined ankles (12 from 1186 ankles) showed well-corticated subfibular ossicle not related to initial injuries. Overall incidence of subfibular ossicle at final follow-up after ankle inversion injury was 39.4% (74/188). Incidence of subfibular ossicle at final follow-up was associated with initial injury grade. As for the morphology of ossicle, 93.2% (55/59) of cases with wafer bone fragment at the time of initial injury became oval or round-shaped subfibular ossicle at final radiograph.

**Conclusions:** The chance of ossicle formation after ankle inversion injury was substantially high in pediatric population. On the basis of the findings of our study, we carefully suggest that majority, if not all, of subfibular ossicles would be posttraumatic in pediatric period.

**Level of Evidence:** Level IV—case series.

**Key Words:** subfibular ossicle, pediatric, ankle inversion injury, avulsion fracture

(*J Pediatr Orthop* 2018;38:e530–e535)

Os subfibulare is commonly defined as a separated ossicle of the distal fibular (subfibular ossicle), although it is also referred to as a sesamoid bone encased within peroneus longus and brevis in some references.[1] In this study, we used the term of "subfibular ossicle" instead of "Os subfibulare" for clarification. Subfibular ossicles have been linked to ankle inversion injury, resulting in disruption of the fibrous or cartilaginous attachment and chronic lateral ankle instability.[2–4] It may cause recurrent irritation of soft tissue surrounding the ossicle, resulting in swelling and subfibular pain.[5]

Despite numerous reports of clinical implication of subfibular ossicles, whether subfibular ossicle is congenital or traumatic remains unclear. In literatures, 2 common theories regarding the etiology of subfibular ossicle have been described. In the first theory, subfibular ossicles are thought to be accessory ossicles resulting from anomalous ossification.[6–8] Mancuso et al[9] have described that an ossicle from anomalous ossification can be differentiated from an avulsion fracture in that it is round to oval in shape with smooth and well-demarcated cortical margins. In the second theory, a subfibular ossicle is regarded as a result of an avulsion fracture in which either a cartilaginous or an osseous fragment is avulsed from the tip of fibula.[10–12] We hypothesized that the majority of subfibular ossicles, if not all, could be preventable posttraumatic sequelae rather than unpreventable developmental anomaly.

However, it is difficult to prove this hypothesis because orthopaedic evaluation for ankle sprain in pediatric population is rarely sought by patients or their parents. Usually benign natural course of ankle sprain in children[4] and high cost for orthopaedic evaluation might be the reasons for such underevaluation of ankle sprain in pediatric population. In Korea, people with ankle sprain often visit orthopaedic specialist in primary care unit because all citizens are fully covered by National Health Insurance System. Orthopaedic specialist with radiographic examination is easily accessible with low cost (<20 dollars payment by the patient).

The objectives of this study were: (1) to assess the pattern of ankle inversion injury in children in a single primary care orthopaedic clinic, and (2) to evaluate the chance of de novo formation of subfibular ossicle after ankle inversion injury in children.

## METHODS

### Study Population

Our study protocol was reviewed and approved by Institutional Review Board of our hospital. Between March 2009 and 2014, 896 pediatric patients (age ranging

From the *Department of Orthopedic Surgery, Seoul National University Hospital, Jongno-gu, Seoul; and †Barun Orthopedic Hospital, Gyeonggi-do, South Korea.

Supported by a grant (NRF-2016R1D1A1B02009379) of the Basic Science Research Program through the National Research Foundation of Korea (NRF) funded by the Ministry of Education, Science, and Technology, Republic of Korea.

The authors declare no conflicts of interest.

Reprints: Doo Jae Lee, MD, Department of Orthopedic Surgery, Seoul National University Hospital, 101 Daehak-no, Jongno-gu, Seoul 110-744, South Korea. E-mail: gotgetto@gmail.com.



DOI: 10.1097/BPO.0000000000001231

from 3 to 15 y) visited a single primary care unit after trauma around the foot and ankle.

After excluding 303 patients with foot injury, ankle fracture including physeal fracture, history of previous foot and ankle pain, skeletal maturity, or with incomplete medical records, 593 patients who were sustaining ankle inversion injury were included in this study. Their medical records were reviewed retrospectively. There were 331 males (range, 3 to 14 y) and 262 females (range, 3 to 12 y) with a mean age of 8.7 years. Patients were classified into 4 groups by age at the index inversion injury (< 5, 6 to 8, 9 to 11, and > 12 y). For evaluating the formation of subfibular ossicles, 188 patients (101 males, 87 females, mean age of 8.7) who were followed up for > 6 months (mean follow-up, 24.5 mo) were selected for analysis.

## Protocol for Evaluation and Treatment After Ankle Inversion Injury

For each pediatric patient who had sustained ankle inversion injury, physical examination and radiographic examination (anteroposterior, lateral, and mortise view of the bilateral ankle) were performed. We carefully performed physical examination to rule out Salter-Harris type I injury of the distal fibular. If there was diffuse tenderness and swelling usually along the epiphyseal plate of distal fibula without focal tenderness on attachment site of anterior talofibular ligament (ATFL) or calcaneofibular ligament, we exclude patient with a diagnosis of Salter-Harris type I injury of the distal fibula in this study. The severity of inversion injury was classified into 3 grades according to physical examination and radiographic findings (Fig. 1). Grade I was defined when there was no abnormal findings in radiograph but symptoms such as mild swelling or localized tender point were present. Grade II was defined when patients had symptoms such as swelling and tender point without avulsion fracture but showing irregularity or blurred epiphysis. Grade III was defined when there were definite avulsion fracture and damage to epiphysis in radiographs. For grade I injury, short leg splint or cast were applied for 1 week and reevaluation was performed after 1 week. Weight-bearing was permitted if tolerable. Immobilization was maintained until the tenderness and swelling were resolved. For grade II or III injury, short leg cast was prescribed for 4 weeks. Generally, follow-up was carried out at an interval of 1 month until there was a full resolution of symptom. Identification of preexisting subfibular ossicle or new formation of subfibular ossicle after ankle inversion injury was evaluated using plain radiographs at each timepoints (initial and final follow-up).

## Data Acquisition and Analysis

The incidence of subfibular ossicle was evaluated based on initial radiographic examination. To analyze the incidence of new subfibular ossicle formation after ankle inversion injury, radiographs of 188 patients who were followed up for > 6 months were evaluated according to the grade of injury. The $\chi^2$ test and linear by linear association were used to determine the statistical significance. Logistic regression analysis was used to find correlation between formation of subfibular ossicle and age of patient group. Cohen unweighted κ was used to find conformity degree between 2 observers in evaluation of existence of avulsion fragment based on initial radiograph and subfibular ossicle based on final radiograph. Statistical significance was considered when $P$-value was <0.05.

# RESULTS

Demographic characteristics of the study population are summarized in in Table 1 and Figure 2. Incidence of grade II injury was the highest in the age group of 6 to 8 years. It was decreased with age with maturation of distal fibular epiphysis. However, incidence of grade II or III injury was quite low in children who were under 5 years old or over 12 years old.

Conformity degree between 2 observers (D.Y.L., D.J.L.) was relatively high on initial classification for


**FIGURE 1.** Radiographic grade of ankle inversion injury in pediatric population. Grade I, no abnormal findings in radiograph (A); grade II, irregularity or blurred epiphysis (white arrow) in radiograph (B); grade III, definite avulsion fracture (black arrow) and damage to epiphysis in radiograph (C).

**TABLE 1.** Demographic Characteristics

| Characteristics | Group I (N = 416) | Group II (N = 118) | Group III (N = 59) |
|---|---|---|---|
| Mean age (y) | 8.92 | 8.06 | 8.46 |
| Sex [n (%)] | | | |
| Male | 231 (56) | 68 (58) | 32 (53) |
| Female | 185 (44) | 50 (42) | 27 (47) |
| Cases (> 6 mo) f/u | 97 | 62 | 29 |
| Follow-up (mo) | 23.0 | 27.0 | 24.3 |
| Ossicle at final f/u [n (%)] | 14 (14) | 40 (65) | 20 (69) |

f/u indicates follow-up.

**TABLE 2.** Ossicle Not Related to Injuries

| Characteristics | N = 12 |
|---|---|
| Overall incidence (%) | 1.0 |
| Ipsilateral:contralateral | 4:8 |
| Sex (N) | |
| Male:female | 5:7 |
| Shape [n (%)] | |
| Oval | 8 (67) |
| Round | 4 (33) |
| Age distribution [n/N (%)] (y) | |
| < 5 | 0/96 (0) |
| 6-8 | 7/504 (1.3) |
| 9-11 | 3/414 (0.7) |
| > 12 | 2/192 (1.0) |

injury grade and identification of subfibular ossicle (Cohen unweighted κ: 0.73 and 0.83, respectively). However, existence of avulsion fragment at initial radiograph and a subfibular ossicle at final radiograph were decided by discussion if there was a discrepancy between the 2 observers.

At initial visit, 1.0% of examined ankles (12 from 1186 ankles of 593 patients) showed well-corticated ossicle not related to initial injuries (Table 2 and Fig. 3). There was no recalled previous trauma history in these cases. In cases with an ipsilateral ossicle at the site of inversion injury (4 ankles), we considered that these ossicles were not made by acute inversion injury because the ossicles were round or oval in shape with smooth and well-corticated margin. Four ankles with a preexisting ossicle in the ipsilateral ankle excluded were for the analysis of new subfibular ossicle formation. However, we cannot recognize the existence of accessory ossification center of the distal fibula which was equivalent to that in medial malleolus[13] in our study population.

Overall incidence of subfibular ossicles at final follow-up after ankle inversion injury was 39.4% (74/188) (Table 1). Subfibular ossicle at final follow-up was associated with initial injury grade (odds ratio: 8.0; $P = 0.001$). Even in grade I injury patients, 14.4% (14/97) showed a subfibular ossicle when they were followed up for over 6 months (Fig. 4).

After grade II or III injuries, 65.9% of patients (60 of 91 cases) had residual ossicles at the final radiograph. Of these 60 cases, 55 (91.7%) showed increase in the size of ossicles while 6 cases showed the same size. No case showed reduction in the size of the ossicle. As for the morphology of ossicle, 92.4% (49 of 53 cases) of patients with wafer bone fragment at the time of initial injury showed oval or round shape subfibular ossicles at final radiograph (Table 3 and Fig. 5).

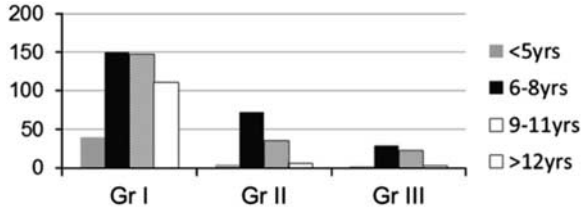


**FIGURE 2.** Distribution of age group and injury grade of the study population.

## DISCUSSION

In this study, we evaluated the incidence of de novo subfibular ossicle formation after ankle inversion injury in pediatric patients who were treated in primary orthopaedic care unit.

Traditionally, the term "os subfibulare" was used to describe accessory ossicles resulting from anomalous ossification.[1,6,7] To the best of our knowledge, although the incidence of accessory secondary ossification center of the lateral malleolus has been reported to be 1% in numerous literatures, [10,13–16] the prevalence of accessory ossification center of lateral malleolus has not been described in a population-based study written in English. Even in the most frequently cited article (and maybe the only peer-reviewed article cited for incidence) by Powell,[13] the exact description was that "a separate lateral malleolar center was observed in one child" in a series of 100 children between the ages of 6 and 12 years. There was no description about the morphology, size, or the location of the accessory ossification center of the lateral malleolus. In this study, we examined 1186 ankles of 593 pediatric patients in a primary orthopaedic care unit and found that the incidence of subfibular ossicles on initial radiograph was about 1.0% (12/1186), similar to a previous report.[13] We could not determine whether subfibular ossicle at initial radiograph was traumatic or congenital. However, the shape of subfibular ossicle at the initial radiograph could not be differentiated from ossicles developed after ankle inversion injury in pediatric population in our study (Figs. 3, 6). Interestingly, we could not find any radiographic figures directly showing accessory ossification center of the lateral malleolus of a child in peer-reviewed literatures which is equivalent to that of medial malleolus.[6–8,13,15,17]

There were 2 main theories supporting accessory ossification center in spite of the lack of direct evidences. The first is the shape of ossicle. Several characteristics of ossicles suggest avulsion lesions, including thin wafer shape of fragments, a sharp angular shape, and conformity with the fracture surface of the malleolus.[5,10,16] On the contrary, ossicle from anomalous ossification can be differentiated from an avulsion fracture in that it is round to oval in shape with smooth and


**FIGURE 3.** A–D, Subfibular ossicles not related to index inversion injury was observed in 1% of the study population.

well-demarcated cortical margins (Fig. 3).[9] However, we showed that the shape of ossicle changed with time in several cases of avulsion fracture. The ossicle showing typical characteristics of avulsion fracture at the time of initial injury might become rounder and larger at the final follow-up (Fig. 6). This result is in agreement with previous reports showing that a long-standing avulsion fracture can also appear with smooth margins.[10,12] The other is the lack of trauma history suggesting ankle fracture. Griffiths and Menelaus[7] have thought that the nonunion of avulsion fractures of the tip of the lateral malleolus is improbable because there has been no history of major trauma to produce avulsion fracture in their cases (n = 3). However, even in the case they presented, radiographs taken at the time of original injury showed a possible fracture of the tip of the lateral malleolus.[7] The ossicle persisted and enlarged at the time of surgery (4 y after the initial injury).[7] Kono et al[8] have reported a patient with os subfibulare thought to have been caused by accessory ossification. The reason was that the patients did not recall an experience of ankle sprain, although he was a competitive soccer player. In this study, we showed that subfibulare ossicle developed even after sustaining grade I ankle sprains which


**FIGURE 4.** Representative case showing the development of subfibular ossicle (B) after sustaining grade I ankle injury (A) without radiographic evidence of previous subfibular ossicle or accessory ossification center (black arrow).

**TABLE 3.** Analysis of Ossicle Shape at Final Follow-up

| Characteristics | | |
|---|---|---|
| No. patients | 60 | |
| Size changing [n (%)] | | |
| Bigger | 55 (91.7) | |
| Sustained | 5 (8.3) | |
| Smaller | 0 | |
| Shape changing [n (%)] | Initial | Follow-up |
| Chip bone | 53 (88.3) | 4 (6.7) |
| Oval | 4 (6.7) | 36 (60) |
| Round | 3 (5) | 20 (33.3) |

required <2 weeks of immobilization clinically. So, even when patients do not recall a trauma suggesting avulsion fracture, the possibility of causative ankle sprain in their pediatric periods cannot be excluded.

In our study, we found that the chance of de novo ossicle formation after pediatric ankle inversion injury was substantially high. There are 2 possible explanations for the development of subfibular ossicle after ankle sprain without avulsion fracture or accessory ossification center. The first is that there might be a misdiagnosis of avulsion fracture of the distal fibula with conventional ankle radiographs in children. Kwak and colleagues have reported that 26% (20/78 ankles) of occult avulsion fracture is misdiagnosed as ankle sprain at initial radiographic examination using conventional radiographic examination, suggesting that the use of anterior talofibular view is needed.[18,19] The other is that chondral avulsion fragment of the ATFL, which might not be visible with plain radiograph, results in subfibular ossicles by later ossification of avulsed fragment. It might be different from traditional teaching that the growth plate is weaker than the ligament and that children who invert the ankle get a Salter-Harris type 1 injury of the distal fibular more frequently than a ligament or avulsion injury.[20,21] We agree that the growth plate is weaker than the ligament itself and we did not observe patients of completely torn ligament in pediatric population before skeletal maturity. However, until the age of 6, fibular ossification has not expanded to the styloid portion of distal fibular where the ATFL and the calcaneofibular ligament are attached.[22] In cases of unossifed fibular insertion area, we think cartilage might be weaker than growth plate. With advent of ultrasonographic examination, chondral avulsion fragment injury of the ATFL might not be visible with plain radiograph, can be diagnosed more accurately. Gleeson et al[23] have reported that ultrasound examination can show a significant subperiosteal hematoma in pediatric patients with normal plain radiograph after ankle inversion injury.

On the basis of the findings of this study, we carefully suggest that the majority, if not all, of subfibular ossicles are posttraumatic. A benign natural course of pediatric ankle sprain and radiographic characteristic of unossified distal fibula might have caused inadequate evaluation and suboptimal management of ankle sprain or avulsion fracture in pediatric population.

For the clinical significance of posttraumatic ossicle formation, we cannot compare clinical outcome between patients with or without ossicle formation, because controlled follow-up was not possible in this study which was analyzed retrospectively in primary orthopaedic clinic setting. However, there are several previous reports in that the symptomatic subfibular ossicles have been linked to ankle inversion injury, resulting in disruption of the fibrous or cartilaginous attachment and chronic lateral ankle instability.[2–4] The subfibular ossicle may cause recurrent irritation of soft tissue surrounding the ossicle, resulting in swelling and subfibular pain.[5] So we carefully suggest that ankle sprain in children should be managed more actively (eg, radiographic examination and cast immobilization when avulsion injury is suspicious) to prevent the development of posttraumatic subfibular ossicle.

There are several limitations of this study. First, although the results of this study suggest that round or oval subfibular ossicle might be a consequence of ankle inversion injury in pediatric period, there was no direct evidence to rule out the existence of accessory ossification center. Second, this study was a retrospective review and the percentage of long-term follow-up was relatively low in a setting of primary


**FIGURE 5.** Representative 2 cases (A, B) showing enlargement and morphologic change of initial avulsed fragment (white arrow) at long-term follow-up which began to show the characteristics of so called "atraumatic os subfibulare (black arrow)."

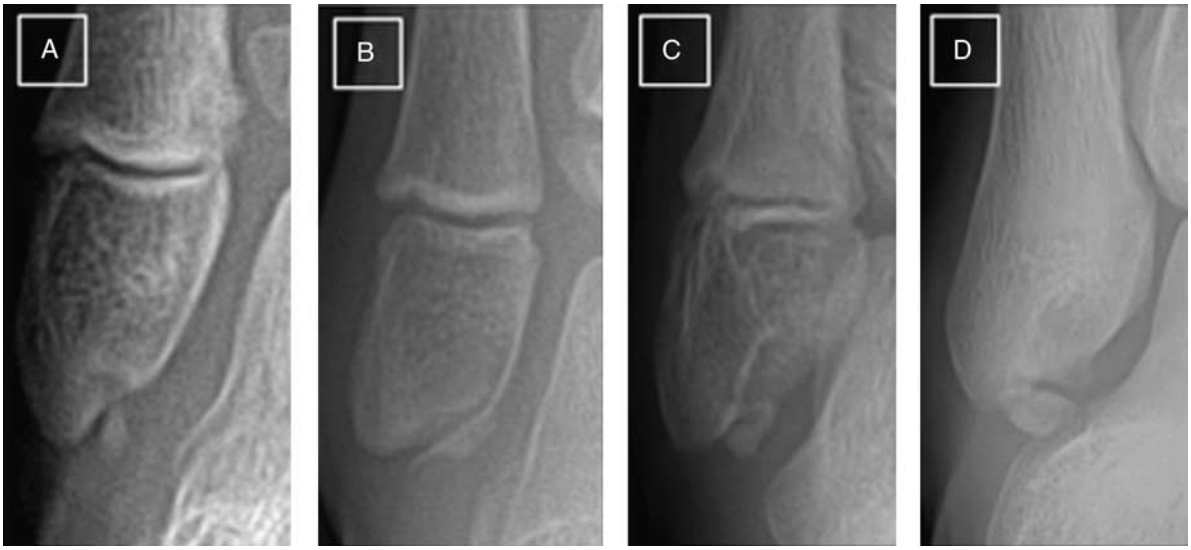


**FIGURE 6.** A–D, Representative 4 cases of de novo subfibular ossicle formation after ankle inversion injury, which was round or oval in shape with smooth and well-demarcated cortical margins at long-term follow-up.

care unit. This might have resulted in selection bias for high incidence of residual ossicles. A prospective cohort study is needed to evaluate the clinical implication of subfibular ossicle. Finally, we could not draw a conclusion on whether accurate diagnosis (eg, by use of ultrasound examination) and more conservative management (eg, cast immobilization for a longer time) could prevent the development of traumatic subfibular ossicle after ankle inversion injury in pediatric population. Further research studies are needed to provide adequate treatment protocol.

## CONCLUSIONS

The chance of subfibular ossicle formation after ankle inversion injury was substantially high in pediatric population. On the basis of the findings of our study, we carefully suggest that majority, if not all, of subfibular ossicle would be posttraumatic in pediatric period.

## REFERENCES

1. Champagne IM, Cook DL, Kestner SC, et al. Os subfibulare. Investigation of an accessory bone. *J Am Podiatr Med Assoc*. 1999; 89:520–524.
2. Ahn HW, Lee KB. Comparison of the modified brostrom procedure for chronic lateral ankle instability with and without subfibular ossicle. *Am J Sports Med*. 2016;44:3158–3164.
3. Hamilton WG, Thompson FM, Snow SW. The modified Brostrom procedure for lateral ankle instability. *Foot Ankle*. 1993;14:1–7.
4. Pill SG, Hatch M, Linton JM, et al. Chronic symptomatic os subfibulare in children. *J Bone Joint Surg Am*. 2013;95:e115; (1–6). [Epub August 24, 2013].
5. Han SH, Choi WJ, Kim S, et al. Ossicles associated with chronic pain around the malleoli of the ankle. *J Bone Joint Surg*. 2008;90: 1049–1054.
6. Bjornson RG. Developmental anomaly of the lateral malleolus simulating fracture. *J Bone Joint Surg Am*. 1956;38-A:128–130.
7. Griffiths JD, Menelaus MB. Symptomatic ossicles of the lateral malleolus in children. *J Bone Joint Surg*. 1987;69:317–319.
8. Kono T, Ochi M, Takao M, et al. Symptomatic os subfibulare caused by accessory ossification: a case report. *Clin Orthop Relat Res*. 2002;399:197–200.
9. Mancuso JE, Hutchison PW, Abramow SP, et al. Accessory ossicle of the lateral malleolus. *J Foot Surg*. 1991;30:52–55.
10. Hasegawa A, Kimura M, Tomizawa S, et al. Separated ossicles of the lateral malleolus. *Clin Orthop Relat Res*. 1996;330:157–165.
11. Berg EE. The symptomatic os subfibulare. Avulsion fracture of the fibula associated with recurrent instability of the ankle. *J Bone Joint Surg Am*. 1991;73:1251–1254.
12. Ferran J, Blanc T. Os subfibulare in children secondary to an osteochondral fracture. *J Radiol*. 2001;82:577–579.
13. Powell H. Extra centre of ossification for the medial malleolus in children. Incidence and significance. *J Bone Joing Surg Br*. 1961;43: 107–113.
14. Mandalia V, Shivshanker V. Accessory ossicle or intraepiphyseal fracture of lateral malleolus: are we familiar with these? *Emerg Med J*. 2005;22:149–152.
15. Karlsson J, Lansinger O. Separate centre of ossification of the lateral malleolus with instability of the ankle joint. *Arch Orthop Trauma Surg*. 1990;109:291–292.
16. Ogden JA, Lee J. Accessory ossification patterns and injuries of the malleoli. *J Pediatr Orthop*. 1990;10:306–316.
17. Paterson FW, Benjamin A. Instability of the ankle due to a separate centre of ossification in the lateral malleolus. *Injury*. 1984;15:330–333.
18. Kwak YH, Lim JY, Oh MK, et al. Radiographic diagnosis of occult distal fibular avulsion fracture in children with acute lateral ankle sprain. *J Pediatr Orthop*. 2015;35:352–357.
19. Haraguchi N, Kato F, Hayashi H. New radiographic projections for avulsion fractures of the lateral malleolus. *J Bone Joint Surg*. 1998;80:684–688.
20. Podeszwa DA, Mubarak SJ. Physeal fractures of the distal tibia and fibula (Salter-Harris type I, II, III, and IV fractures). *J Pediatr Orthop*. 2012;32(suppl 1):S62–S68.
21. Marsh JS, Daigneault JP. Ankle injuries in the pediatric population. *Curr Opin Pediatr*. 2000;12:52–60.
22. Love SM, Ganey T, Ogden JA. Postnatal epiphyseal development: the distal tibia and fibula. *J Pediatr Orthop*. 1990;10:298–305.
23. Gleeson AP, Stuart MJ, Wilson B, et al. Ultrasound assessment and conservative management of inversion injuries of the ankle in children: plaster of Paris versus Tubigrip. *J Bone Joint Surg*. 1996; 78:484–487.