Observational Study

Medicine®

OPEN

Mini-incisional entropion repair for correcting involutional entropion

Full description and surgical outcome

Jisang Han, MD[a], Shin-Hyo Lee, PhD[b], Hyun Jin Shin, MD, PhD[c,*]

Abstract

The aim of the study was to report the surgical outcome of mini-incisional correction method to treat involutional entropion.

This is a retrospective interventional case series of 46 eyelids in 31 patients with involutional entropion and significant ocular irritation. In this technique, after turning the lower eyelid inside out, threads are introduced into it through the conjunctiva close to the inferior fornix. The lower lid retractor and tarsus are then connected using threads. These threads are applied at 3 locations of the lower eyelid and tightening them results in the eyelid being everted and the correction of entropion. Surgical success was defined as no contact between the eyelashes and the globe during forced closure of the eyelids. Surgical failure was defined as persistence of the eyelashes remaining in contact with the globe or cosmetic dissatisfaction.

During the mean follow-up period of 22.1 months (range, 12–34 months), 43 of the eyelids (93.5%) were successfully corrected. Two patients (3 eyelids) experienced recurrence: 1 had involutional entropion combined with a cicatricial component, and the other had blepharospasm and apraxia of eyelid opening related to Parkinsonism. No postoperative complications such as overcorrection, suture-knot exposure, or ocular irritation were observed.

Our mini-incisional entropion repair is based on reinforcement of the lower eyelid retractors using transconjunctival buried sutures. This technique is a quick, simple, and predictive for involutional entropion repair, and has a high success rate.

Keywords: involutional entropion, lower eyelid retractors, mini-incisional repair

1. Introduction

Entropion is as an eyelid malposition marked by an inward turning of the eyelid margin that results in ocular irritation, discharge, erythema, and tearing. Involutional entropion is the most common form of entropion, and it frequently requires surgical repair.[1] The classic triad known to cause involutional entropion is dehiscence of the lower lid retractors, horizontal lid laxity of the tarsus and canthal tendon, and overriding of the preseptal orbicularis oculi muscle.[2,3] Methods for correcting involutional entropion aim at addressing the underlying factors. Among them, dehiscence or attenuation of the lower lid retractors could be the primary cause of involutional entropion, and thus reinforcement of the lower lid retractors is important surgical step.[4,5]

In 2010, Shimizu et al first introduced nonincisional correction method for blepharoptosis based on the use of transconjunctival buried sutures.[6] These suspension sutures plicate the superior levator palpebral and Müller muscles and can advance the levator aponeurosis, resulting in the improvement of blepharoptosis. Those authors documented that the method has the advantage of being relatively simple and minimizes injury to the eyelid tissue, with a relatively high success rate (94.7% in 390 patients) in the presence of mild-to-moderate ptosis. Lee et al also reported the excellent predictability of a nonincisional correction method, with a success rate of 89% in 245 patients.[7]

The upper and lower eyelids are considered anatomically analogous structures, with the levator palpebral and Müller muscle in the upper eyelid corresponding to the lower lid retractor in the lower eyelid.[8] We thought that a nonincisional correction method for blepharoptosis of the upper eyelid could be applied to correct involutional entropion of the lower eyelid by reinforcing the dehiscenced or attenuated lower lid retractors. The aim of this study was to describe a novel method for mini-incisional entropion repair and to characterize its surgical outcomes.

2. Materials and methods

This retrospective study involved patients who underwent mini-incisional entropion repair for involutional entropion and

Editor: Yan Li.

This work was supported by the National Research Foundation of Korea (NRF) grant funded by the Korea government (MSIT) (no: 2019R1H1A1035595).

The authors have no funding and conflicts of interest to disclose.

Supplemental Digital Content is available for this article.

Funding: This work was supported by the National Research Foundation of Korea(NRF) grant funded by the Korea government(MSIT) (No. 2019R1H1A1035595)

[a] Department of Ophthalmology, Kangbuk Samsung Hospital, Sungkyunkwan University School of Medicine, [b] Department of Anatomy, Research Institute of Medical Science, Konkuk University School of Medicine, [c] Department of Ophthalmology, Research Institute of Medical Science, Konkuk University Medical Center, Konkuk University School of Medicine, Seoul, Republic of Korea.

[*] Correspondence: Hyun Jin Shin, Department of Ophthalmology, Konkuk University Medical Center, Konkuk University School of Medicine, 120 Neungdong-ro, Gwangjin-gu, Seoul 05030, Republic of Korea (e-mail: shineye@kuh.ac.kr).

Medicine (2019) 98:33(e16731)

Received: 17 February 2019 / Received in final form: 2 July 2019 / Accepted: 14 July 2019

http://dx.doi.org/10.1097/MD.0000000000016731

significant ocular irritation that was resulting in tearing, photophobia, discharge, and keratitis at Konkuk University Hospital, Seoul, Korea between January 2014 and December 2017. The study was performed in accordance with the principles of the Declaration of Helsinki, and the institutional review board and ethics committee at Konkuk University Medical Center approved the study protocol. Informed consent was obtained from all patients prior to performing the procedures. Medical records were screened, and surgical outcomes, complications, and recurrence rates were assessed.

All patients were operated on by a single surgeon (HJS) using the mini-incisional entropion repair method. Only patients with a follow-up period of at least 12 months were included. Preoperative lower eyelid laxity was evaluated by the distraction test, which was judged as positive when the distance from the globe to the lower eyelid margin was more than 8 mm.[9] Patients with horizontal lid laxity also received a horizontal tightening procedure using lateral canthopexy. Patients were assessed at 1, 2, 3, 6, and 12 months postoperatively. During an office examination, the patients were also asked if they considered the surgery to be cosmetically successful and the ocular irritation had improved. Surgical success was defined as no inward turning of the eyelid during the provocation test (forcefully closing the eyelids) and when the patient expressed cosmetic satisfaction and improvement of ocular irritation.

2.1. Surgical technique

The overall concept of the novel surgical procedure is introduced in Figure 1 and Supplemental Video 1, http://links.lww.com/MD/D156. The 5 main steps are described in the following sections.

2.1.1. Step 1. A small skin incision line is drawn at 2 mm below the eyelashes in 3 places: 1 mm medial to the medial limbus, 1 mm lateral to the lateral limbus, and at the center of the pupil (point A, Figs. 1A and 2A). The conjunctiva and the eyelid are then infiltrated with 2 mL of 2% lidocaine and 1:100,000 epinephrine. The skin at the points marked on the eyelid is penetrated with a scalpel to make small slits shorter than 2 mm in which the suspension sutures are enfolded at the end of the operation. A strip of the orbicularis oculi muscle is excised within the incision by using small scissors. A 5/0 nylon traction suture is applied at the upper margin of the central part of the tarsus and suspended in the anterosuperior direction. This suspension provides exposure of the fornix of the inferior conjunctiva, which makes the subsequent procedures easier to perform.

2.1.2. Step 2. After turning the lower eyelid inside out, a 7/0 nylon suture is introduced into the conjunctiva (point B, Figs. 1A and 2C) from the skin incision point on the eyelid by piercing the lower tarsal margin (Fig. 2B). The needle is then reinserted at the same point of the conjunctiva through which it was extracted and is passed through subconjunctivally as close to the inferior conjunctiva fornix as possible (point C, Figs. 1A and 2D).

2.1.3. Step 3. The needle is reinserted at the same point of the conjunctiva through which it was extracted (point C, Fig. 1A) and guided more deeply to involve the lower eyelid retractors underlying the conjunctiva (Fig. 2E). The thread is then temporarily extracted from the conjunctiva at the level of the lower margin of the tarsus (point B, Fig. 1A). A 7/0 nylon suture is guided to pierce the lower tarsal border at point B again (Fig. 2F), and then it is extracted from the minor slit previously made in step 1 (Fig. 2G).

2.1.4. Step 4. The lower eyelid is returned to its original position (Fig. 1B) and then the 7/0 nylon is tightened. As the suture is tightened, a dimple appears on the conjunctiva due to the loosened or detached lower lid retractor being tucked in. The knot of the suture is buried inside the minor slit of the lower eyelid (Fig. 2H). These procedures are performed at 3 positions along the eyelid.

2.1.5. Step 5. After confirming improvement in the direction of the eyelashes (Fig. 1C), the skin is closed with simple interrupted 7/0 nylon sutures that include the underlying orbicularis oculi muscle (Fig. 2I). Finally, the 5/0 nylon traction suture attached to the tarsus is removed. The stitches are removed 1 week later in the outpatient clinic.

3. Results

Clinical characteristics of all study eyes are listed in Table 1. The study included 46 lower eyelids of 31 patients (16 females, 15 males; mean age 73 years, age range 55–83 years) who underwent operations using the new mini-incisional entropion repair. All patients in our study were Asian without ethnicity

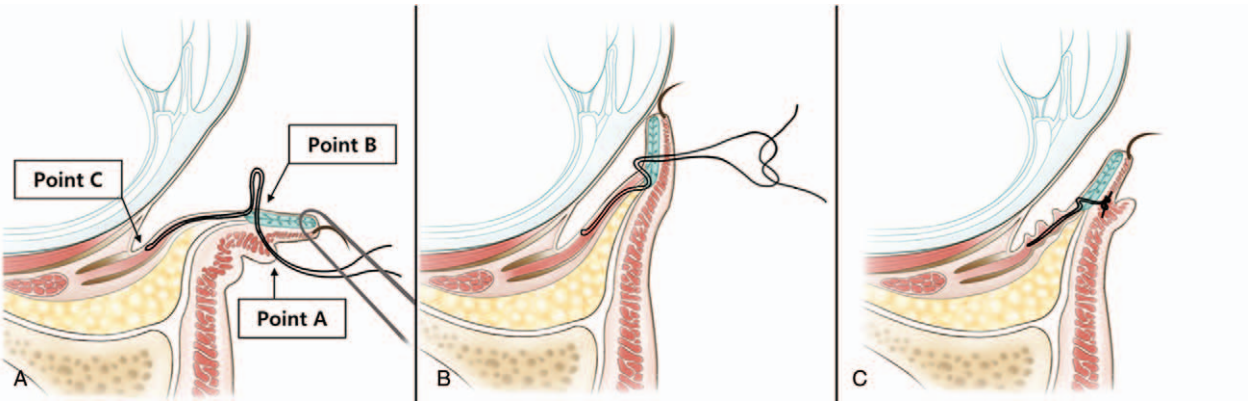

Figure 1. (A) Schema of how the lower lid retractor is involved. Point A is the skin incision site. Points B and C indicate the points on the conjunctival side at which the threads are introduced and pulled out. (B, C) As the 7/0 nylon thread is tied, the knot is buried inside the skin of the lower eyelid. The sites at which the knots are enfolded forms a barrier to prevent the preseptal orbicularis oculi muscle overriding the pretarsal orbicularis oculi muscle.

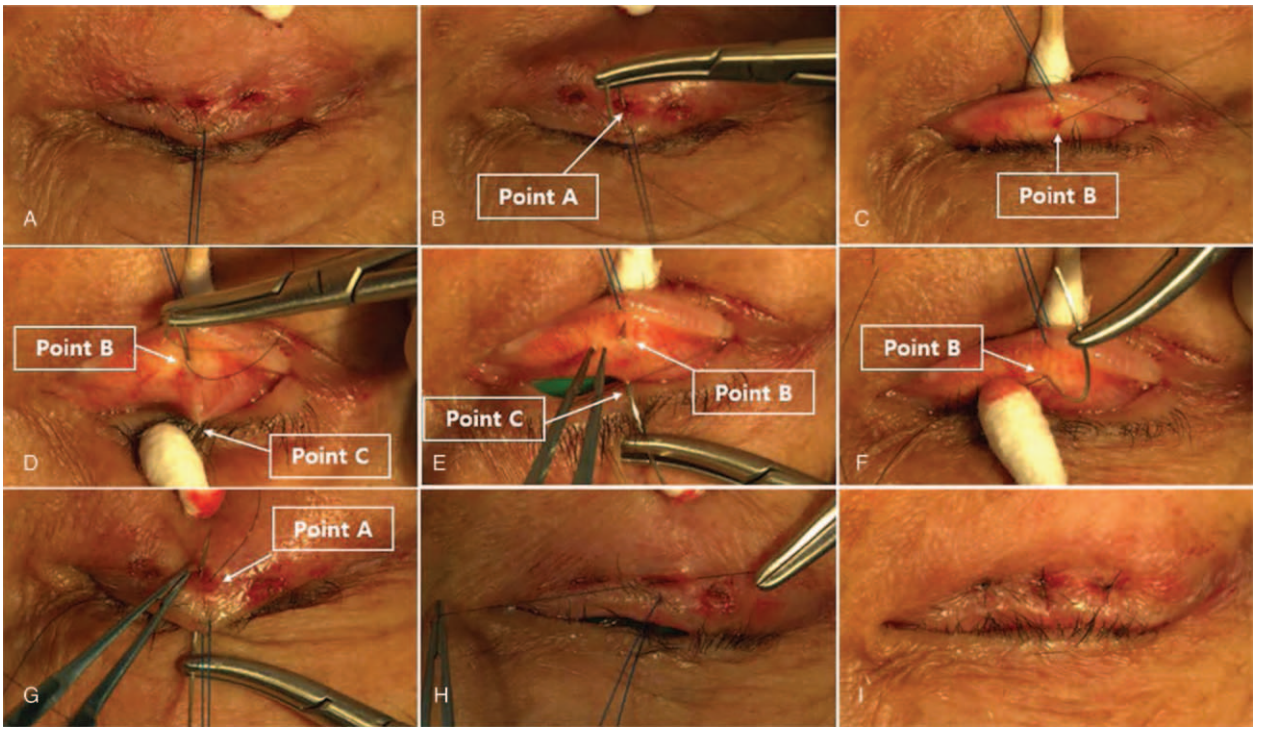

Figure 2. (A) Applying a traction suture at the upper margin of the tarsus. (B) and (C) 7/0 nylon thread is inserted using a large round needle from point A (skin) to point B (conjunctiva) located at the inferior tarsal margin. (D) The needle is reinserted at point B and passes through subconjunctivally to point C. (E) The needle is reinserted at point C and guided more deeply to involve the lower lid retractor underlying the conjunctiva. (F, G) After piercing point B (tarsus), the thread is again extracted at point A. (H) The thread is tied, and the knot is buried inside the skin of the lower eyelid. (I) The skin is closed with simple interrupted 7/0 nylon sutures that included the underlying orbicularis oculi muscle.

variations. Fifteen cases were bilateral, and 16 cases were unilateral. The mean follow-up period was 22.1 months (range, 12–34 months). No intraoperative complications occurred, with the surgery performed under local anesthesia and finished within 10 minutes per side in all cases.

Based on our defined criteria, the outcome was successful for 43 eyelids (93.5%). Lateral canthopexy was additionally performed in the 17 patients (25 eyelids) with simultaneous horizontal lid laxity. The success rate in the 14 patients (21 eyelids) who received only mini-incisional entropion repair without lateral canthopexy was 100%. Two patients (3 eyelids) in our cohort had a history of eyelid surgery for involutional entropion at another hospital. These patients also had a successful outcome following reoperation using mini-incisional entropion repair. No postoperative complications such as overcorrection, contour deformity, lower lid retraction, suture-knot exposure, or ocular irritation were recorded. Also, none of the patients expressed cosmetic dissatisfaction. Figure 3 shows preoperative and postoperative photographs of a patient who underwent mini-incisional entropion correction.

Two patients (3 eyelids) experienced recurrence. One patient who had involutional entropion combined with a cicatricial component experienced recurrence at 4 months after surgery. The other one who had blepharospasm and apraxia of eyelid opening related to Parkinsonism experienced recurrence at 5 months after surgery. Both patients were reoperated successfully: one using the Wies procedure and the other using transcutaneous reinsertion of the lower lid retractor.

Table 1

Clinical characteristics of all study eyes.

Clinical variable	Mini-incisional entropion repair (46 eyelids)
Mean age, yr	73 (range, 55–83)
Sex, male/female	16/15
Laterality, right/left	24/22
Mean follow–up, mo	22.1 (range, 12–34)
Previous entropion surgery	2 (9%)
Horizontal lid laxity	25 (54%)
Postoperative complication*	0 (0%)
Recurrence	3 (6.5%)
Surgical success rate	43 (93.5%)

* Overcorrection, contour deformity, suture-knot exposure, ocular irritation, and cosmetic dissatisfaction.

4. Discussion

We have described a novel surgical technique for involutional entropion correction using transconjunctival buried sutures that enable the engaging and advancement of the lower lid retractors in the inferior tarsal plate border. This method is effective at repairing inverted eyelid with minimal injury to the eyelid tissue.

Our technique is similar to those described in previous reports of mini-incisional correction methods for blepharoptosis that involve the superior levator palpebral and Müller muscles.[6,7] In the present study, we applied a buried-suture technique to the lower eyelid to reinforce the disinserted or attenuated lower lid retractor. Our use of 3 knots made it possible to precisely correct

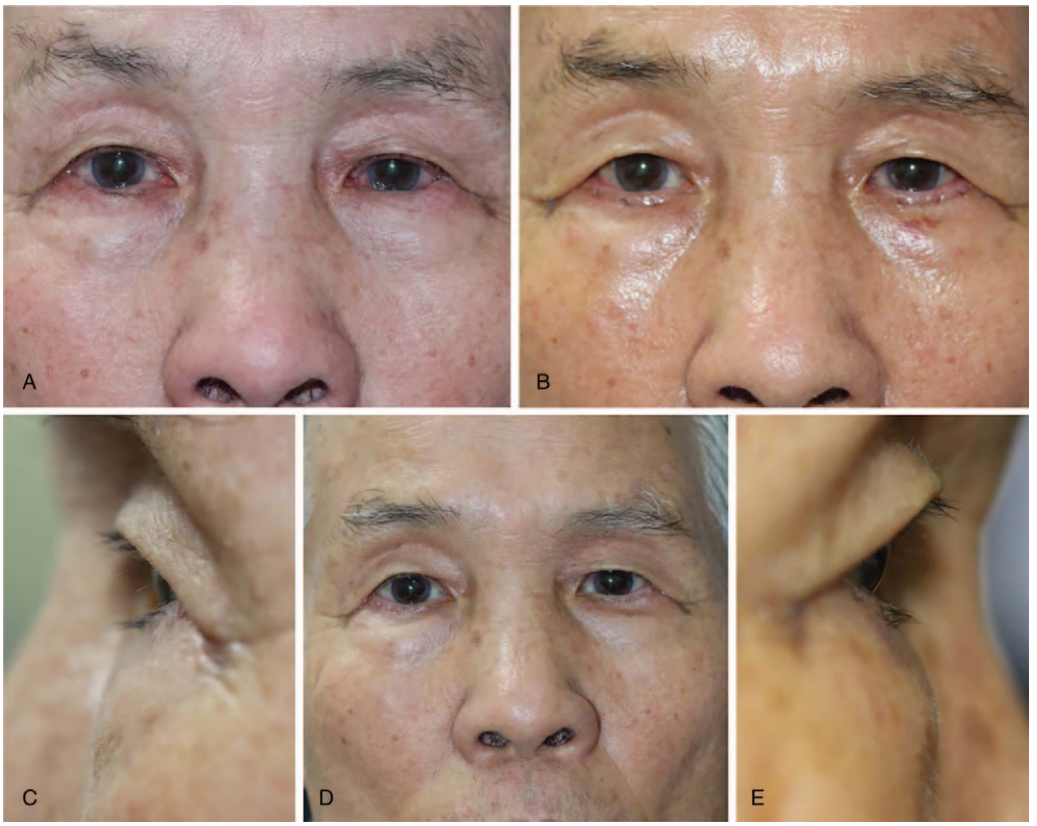

Figure 3. (A) Preoperative state of a 74-year-old man with involutional entropion. (B) Appearance at 1 week postoperatively showing minimal wound swelling. (C–E) At 20 months postoperatively, there were no inverted eyelashes in contact with the globe (C, left side; E, right side).

the involutional entropion. Our method also increased the strength of the correction by removing a strip of the orbicularis oculi muscle through the very small subciliary incision and incorporating the underlying orbicularis oculi muscle in the suturing for achieving skin closure. Both of these features cause adhesion between the anterior and posterior lamella and prevent overriding of the preseptal orbicularis oculi muscle.

Various surgical techniques are used to repair involutional entropion. The simplest and most convenient method is to place full-thickness eyelid-everting sutures (Quickert sutures), which generates an anterior rotational vector to change the direction of the eyelash and prevent overriding of the preseptal orbicularis oculi muscle. The main limitation of this procedure is its high recurrence rate, which is reportedly 22% to 58.8% during a mean follow period 18 to 34.5 months.[10–13] The transcutaneous or transconjunctival lower lid retractor reinsertion procedure (also called Jones retractor plication) is one of the most commonly performed operations, and it involves reinsertion of the detached lower lid retractors to the anterior border of the tarsal plate. Although that procedure has the advantage of direct visualization of the pathologic tissues and allows for removal of the pretarsal orbicularis oculi muscle and redundant skin, it has been criticized for its high technical difficulty, time requirement, and potential risk of secondary ectropion and retraction.[14–16]

Our entropion correction method has the following advantages. First, unlike the Quickert everting suture, mini-incisional entropion repair can fundamentally correct the major pathogenesis of involutional entropion by plicating and reattaching the lower eyelid retractors to the tarsal plate using transconjunctival suspension sutures. The present study has demonstrated that our entropion correction method has a lower recurrence rate than those reported previously for Quickert sutures (6.6% vs 22–58.8%, respectively). Second, since invasion to the eyelid is minimized in this method, our method leaves no visible scars and shortens the period of postoperative pain, swelling, and discomfort to only 3 to 4 days. This means that patients can return to their normal lives almost immediately. Third, besides a shortened recuperation time, this procedure is technically easy to teach and learn, and can easily be repeated if necessary. Our cohort of patients included 3 relapsed cases who had previously received involutional entropion surgery at another hospital; those patients were successfully reoperated using mini-incisional entropion repair in the same way as the other treatment-naïve cases. Lastly, mini-incisional entropion repair was considered safe. There were no complications, including eye irritation or corneal abrasion from exposed sutures material on the conjunctival surface, contour irregularity of eyelid, and over-correction (e.g., eyelid ectropion and retraction) as a result of the procedure.

We performed the surgery without asking the patients to stop their thrombolytic medications. Despite half of the patients in our cohort taking thrombolytic agents such as aspirin and warfarin, there were no intra- or postoperative complications associated with bleeding. This feature is highly advantageous for elderly patients who have accompanying systemic diseases such as diabetes mellitus, hypertension, or angina and are taking

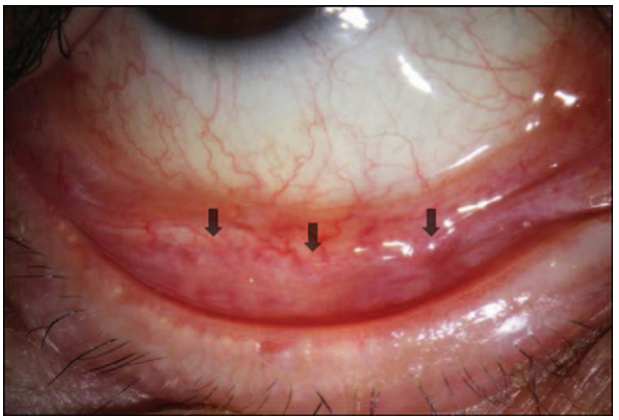

Figure 4. At 20 months postoperatively, a dimple (arrows) still appears on the palpebral conjunctiva due to adhesion formation around the suspension sutures (same patient as in Fig. 3).

medications such as anticoagulants.[17] Kent and Custer reported that 40% of patients undergoing oculoplastic surgery were being treated with anticoagulants, and that discontinuing anticoagulants may increase cerebrovascular or cardiovascular events in some patients.[18] Thus, our surgical method has advantages such as a shorter operation time and less bleeding when correcting involutional entropion in elderly patients compared to the standard lower lid retractor reinsertion surgery.

The longevity of the favorable outcomes of the present correction method could have been questioned. Indeed, the authors were themselves initially unsure about the long-term effects of this method, and so explained to their patients that the probability of relapse might by 30% to 40%. However, the results turned out much better than this initial expectation, with a final success rate of 91.4%. This stability of the suspension method can be attributed to the formation of scar tissue around the suspension sutures. In the early stages after the operation, the eyelid is maintained at the corrected position solely by the 7/0 nylon sutures, which might loosen over time. However, scar tissue then forms around the sutures that maintains the reinforcement effect despite loosening of the suspension sutures (Fig. 4), and so a long-lasting correction effect is expected.

The main limitation of the present study stems from the combined surgery for lateral canthopexy required in 25 eyelids (54%). To assess the effect of this new surgical technique alone, it should have been performed without an adjunctive procedure. However, in the clinical situation it is not feasible to follow-up patients without providing appropriate treatment, which in the present study involved correcting horizontal laxity. However, it was encouraging to see a success rate of 100% in 21 eyelids (46%) who underwent mini-incisional entropion repair alone. This could be sufficient evidence that mini-incisional entropion repair itself will be a reliable procedure for treating involutional entropion. In addition, because the number of recurrences is likely to keep increasing as the follow-up lengthens, the true recurrence rate might be a little higher once all of our patients complete the 5-year postoperative follow-up period.

In conclusion, the authors have developed a safe, minimally invasive, and effective correction method for involutional entropion. Our method involves applying threads without making major incisions, and the inverted eyelids are corrected using suspension sutures applied between the tarsus and the lower eyelid retractors. The technical ease, rapidity, and low bleeding risk make the present method a useful treatment option for involutional entropion in elderly patients.

Author contributions

Data curation: Shin-Hyo Lee.
Formal analysis: Shin-Hyo Lee.
Project administration: Hyun Jin Shin.
Resources: Hyun Jin Shin.
Supervision: Hyun Jin Shin.
Validation: Hyun Jin Shin.
Writing – original draft: Jisang Han.
Writing – review & editing: Jisang Han, Hyun Jin Shin.
Hyun Jin Shin orcid: 0000-0002-3563-8042.

References

[1] Pereira MG, Rodrigues MA, Rodrigues SA. Eyelid entropion. Semin Ophthalmol 2010;25:52–8.
[2] Marcet MM, Phelps PO, Lai JS. Involutional entropion: risk factors and surgical remedies. Curr Opin Ophthalmol 2015;26:416–21.
[3] Damasceno RW, Osaki MH, Dantas PE, et al. Involutional entropion and ectropion of the lower eyelid: prevalence and associated risk factors in the elderly population. Ophthalmic Plast Reconstr Surg 2011;27:317–20.
[4] Jones LT, Reeh MJ, Wobig JL. Senile entropion. A new concept for correction. Am J Ophthalmol 1972;74:327–9.
[5] Benger RS, Musch DC. A comparative study of eyelid parameters in involutional entropion. Ophthalmic Plast Reconstr Surg 1989;5:281–7.
[6] Shimizu Y, Nagasao T, Asou T. A new non-incisional correction method for blepharoptosis. J Plast Reconstr Aesthet Surg 2010;63:2004–12.
[7] Lee H, Lee M, Bae S. Blepharoptosis correction transconjunctivally using buried suture method: a prospective cohort study. Int J Surg 2016;25:9–16.
[8] Kakizaki H, Malhotra R, Madge SN, et al. Lower eyelid anatomy: an update. Ann Plast Surg 2009;63:344–51.
[9] Lee H, Takahashi Y, Ichinose A, et al. Comparison of surgical outcomes between simple posterior layer advancement of lower eyelid retractors and combination with a lateral tarsal strip procedure for involutional entropion in a Japanese population. Br J Ophthalmol 2014;98:1579–82.
[10] Jang SY, Choi SR, Jang JW, et al. Long-term surgical outcomes of Quickert sutures for involutional lower eyelid entropion. J Craniomaxillofac Surg 2014;42:1629–31.
[11] Rougraff PM, Tse DT, Johnson TE, et al. Involutional entropion repair with fornix sutures and lateral tarsal strip procedure. Ophthalmic Plast Reconstr Surg 2001;17:281–7.
[12] Wright M, Bell D, Scott C, et al. Everting suture correction of lower lid involutional entropion. Br J Ophthalmol 1999;83:1060–3.
[13] Meadows AE, Reck AC, Gaston H, et al. Everting sutures in involutional entropion. Orbit 1999;18:177–81.
[14] Erb MH, Uzcategui N, Dresner SC. Efficacy and complications of the transconjunctival entropion repair for lower eyelid involutional entropion. Ophthalmology 2006;113:2351–6.
[15] Hedin A. Senile entropion - cure rate by retractor tightening and horizontal shortening. Acta Ophthalmol Scand 1997;75:443–6.
[16] Kakizaki H, Zako M, Kinoshita S, et al. Posterior layer advancement of the lower eyelid retractor in involutional entropion repair. Ophthalmic Plast Reconstr Surg 2007;23:292–5.
[17] Ing E, Douketis J. New oral anticoagulants and oculoplastic surgery. Can J Ophthalmol 2014;49:123–7.
[18] Kent TL, Custer PL. Bleeding complications in both anticoagulated and nonanticoagulated surgical patients. Ophthalmic Plast Reconstr Surg 2013;29:113–7.