Diverse Patterns and Clinical Significance of ^{11}C-Methionine PET in Dysembryoplastic Neuroepithelial Tumors

Joo Whan Kim, MD, Yeon-koo Kang, MD,† Jin Chul Paeng, MD, PhD,† Seung-Ki Kim, MD, PhD,* Byung Chan Lim, MD, PhD,‡ Ki Joong Kim, MD, PhD,‡ and Ji Hoon Phi, MD, PhD**

Purpose: Dysembryoplastic neuroepithelial tumors (DNETs) are slow-growing epilepsy-associated tumors. Low or normal ^{11}C-methionine (MET) PET uptake helps to differentiate DNETs from other low-grade gliomas. However, diverse MET-PET uptake in DNETs has been observed. The aim of this study is to measure the clinical significance and prognostic value of MET-PET in DNET management.

Patients and Methods: Retrospective review of 26 DNET patients was done. Clinical characteristics, radiologic findings, and visual and quantitative MET-PET results were analyzed. PET uptake was calculated as the tumor–to–homotopic mirror ratio (TNR_m) and tumor–to–contralateral cortex ratio (TNR_c). The clinical activity of the tumors at the time of PET was classified into active and quiescent groups. The surgical outcome was defined as a composite of 2 different aspects: tumor progression and/or clinical events such as seizure recurrence or tumor bleeding.

Results: Twenty-seven MET-PET examinations (20 initial MET-PET and 7 MET-PET during follow-up) were included. Clinically active tumors at the time of PET presented significantly higher values of TNR_m and TNR_c than quiescent tumors. High MET-PET uptake by visual grading, $TNR_m \geq 1.90$, and $TNR_c \geq 1.85$ exhibited poor prognosis for event-free survival.

Conclusions: MET-PET uptake correlates well with the clinical behavior of DNETs at the time of PET examination. Moreover, High MET-PET uptake is closely related to seizure recurrence if tumors are not entirely resected. Efforts to achieve gross total resection should be made for DNETs with high MET-PET uptake.

Key Words: dysembryoplastic neuroepithelial tumor, methionine PET, outcome, epilepsy

(*Clin Nucl Med* 2022;47: 1040–1047)

Dysembryoplastic neuroepithelial tumors (DNETs) are very rare, slow-growing epilepsy-associated tumors that predominantly occur in children and young adults. Since the first introduction of the terminology by Daumas-Duport et al,[1] DNETs remain a distinct disease in the latest 2021 World Health Organization classification due to their characteristic histology and clinical features. DNETs have been regarded as indolent, quiescent tumors with a favorable clinical course even when gross total resection (GTR) was not achieved.[1,2] Contrary to earlier studies, recurrence does not occur infrequently, and reoperation rates have been reported in up to 20% to 30% of patients with DNETs.[3,4]

Although DNETs are glioneuronal tumor mainly driven by alterations of an oncogene, FGFR1, the clinical burden of epilepsy often outweighs the oncological reality.[5] Not surprisingly, DNETs are classified as representative long-term epilepsy-associated tumors along with ganglioglioma.[6] Seizure outcomes with resection of DNETs have shown favorable results, and GTR is the most important factor related to seizure freedom in most studies.[7,8] In terms of oncologic outcomes, despite case reports of tumor recurrence after GTR, GTR is widely accepted as the most important factor for achieving a favorable outcome in the treatment of DNETs.[9,10]

Despite its significance, the GTR of DNETs is not easy to achieve for several reasons. First, the tumor margin is inconspicuous on MRI as well as in the surgical field because most DNETs show poor gadolinium enhancement and harbor complex histologic architectures admixed with focal cortical dysplasia (FCD).[11,12] Second, many DNETs develop in the eloquent areas involving the motor cortex, pyramidal tract, and visual pathways. Finally, the existence of satellite lesions defined as small separate nodules in the vicinity of the main masses makes GTR of DNET more challenging.[13] Because GTR cannot be attained in all DNETs operated on, it is crucial to predict the clinical course of a tumor for adequate follow-up and surveillance.

^{11}C-Methionine (MET) PET shows good correlation with the proliferative and metabolic activity of lesions and is therefore widely used for characterizing brain tumors.[14,15] Previous report of MET-PET findings on DNETs shows variable uptake, which differs from those of FCD and ganglioglioma.[16] Unlike FCD, DNET showed subtle increased MET-PET uptake and is also distinguishable from ganglioglioma, which shows higher uptake akin to other glial neoplasms. Similar MET-PET findings of DNETs have been reported thereafter.[17,18] However, it is not known why the variability of MET-PET appears in DNETs, and we hypothesized that this variability reflects the biological nature of DNETs and that it is possible to predict the clinical behavior of the tumor with MET-PET. Herein, we present the results of MET-PET uptake and determine its clinical impact on DNETs.

PATIENTS AND METHODS

Patients and Surgical Management

From June 1997 to August 2021, 43 patients underwent surgery and were diagnosed with DNETs. Of 43 patients, 30 patients had MET-PET data. Two patients with insufficient follow-up and 2 others with unquantifiable PET data were excluded. Therefore, 26 patients with 27 MET-PET examinations were retrospectively reviewed. MET-PET was performed for preoperative diagnosis at first presentation (initial MET-PET) and/or for evaluation of tumor recurrence when suspicious findings emerged in surveillance MRI (follow-up MET-PET).

The surgical procedure used was lesionectomy without invasive monitoring. The extent of resection was determined by postoperative

Received for publication June 8, 2022; revision accepted July 18, 2022.
From the *Division of Pediatric Neurosurgery, †Department of Nuclear Medicine, and ‡Department of Pediatrics, Seoul National University Children's Hospital, Seoul National University College of Medicine, Seoul, South Korea.
Conflicts of interest and sources of funding: The authors declare that they have no conflicts of interest. This study was jointly supported by a grant from the Seoul National University Hospital (no. 26-2019-0010; to J.H.P.) and Creative-Pioneering Researchers Program through Seoul National University (no. 800-20210571; to J.H.P.).
J.W.K. and Y.-k.K. have contributed equally to this work and share first authorship.
Correspondence to: Ji Hoon Phi, MD, PhD, Division of Pediatric Neurosurgery, Seoul National University Children's Hospital, Seoul National University College of Medicine, 03080, 101 Daehak-ro, Jongno-gu, Seoul, South Korea. E-mail: phijh@snu.ac.kr; Jin Chul Paeng, MD, PhD, Department of Nuclear Medicine, Seoul National University Children's Hospital, Seoul National University College of Medicine, 03080, 101 Daehak-ro, Jongno-gu, Seoul, South Korea. E-mail: paengjc@snu.ac.kr.

ISSN: 0363-9762/22/4712–1040
DOI: 10.1097/RLU.0000000000004400

MRI as follows: GTR, no visible residual tumor including all satellite lesions; near-total resection (NTR), complete removal of the main mass with some residual satellite lesions; subtotal resection (STR), grossly identifiable residual tumor (<10% of initial volume); and partial resection (PR), residual tumor more than 10% of initial volume. Seizure outcome was evaluated according to the Engel classification.[19] The clinical activity of the tumor was divided into active and quiescent groups according to the clinical features of the patients. An active tumor was defined as the presence of uncontrolled seizures despite antiseizure medications, image-verified growth of the tumor, or recent tumor bleeding. A quiescent tumor was associated with clinical features of well-controlled seizures, no evidence of growth, or other changes of the tumor according to MRI.

This study protocol was approved by the local institutional review board (no. 2110-067-1261) and was conducted according to the Helsinki Declaration.

Image Acquisition and Analysis of MET-PET

PET image acquisition was performed with a dedicated PET/CT scanner (Biograph mCT 40; Siemens Healthineers, Erlangen, Germany). Ten minutes after injection of 7.4 MBq/kg MET, PET images were obtained for 10 minutes, after the acquisition of corresponding nonenhanced CT images. PET images were reconstructed with an ordered subset expectation maximization algorithm, and CT-based attenuation correction and scatter correction were applied.

First, MET-PET images were visually assessed to classify lesions as having low, moderate, or high uptake. Low or high uptake was defined as uptake clearly lower or higher than the adjacent normal brain cortices. For quantitative analysis, PET images were spatially coregistered with preoperative MRI obtained on the day closest to the PET acquisition date. A region of interest (ROI) for a tumor was manually drawn on transaxial images of nonenhanced T1-weighted MRI. The contralateral homotopic mirror region and a 1.5-cm–sized sphere of the contralateral cortex region were considered reference ROIs. The SUV_{max} of tumors and mean SUV of reference ROIs (M_{mean} and C_{mean} for contralateral homotopic mirror regions and contralateral cortex regions, respectively) were measured. Finally, the tumor-to-normal ratio (TNR) was defined as the tumor–to–homotopic mirror ratio ($TNR_m = SUV_{max}/M_{mean}$) or the tumor–to–cortex ratio ($TNR_c = SUV_{max}/C_{mean}$), which is the quantitative parameter to adopt for further analyses.

Visual assessment and quantitative analysis were performed by 2 experienced nuclear medicine physicians. PET-MRI coregistration and quantitative analysis were performed by using dedicated image analysis software (MIM 6.7.10; MIM Software Inc, Beachwood, OH).

Outcome Assessment and Statistical Analyses

The surgical outcome was a composite of 2 different aspects: tumor progression and/or clinical events such as the recurrence of seizures or bleeding from the residual tumor. For the analysis of event-free survival (EFS), EFS for all 27 examinations was analyzed as a whole and EFS for 15 examinations with incomplete resection (NTR, STR, or PR) was analyzed separately because GTR has overwhelming impacts on all surgical outcomes of DNETs, regardless of MET-PET uptake. The EFS period was calculated as the time interval from the prior operation date to the date of the clinical event (eg, seizure recurrence or tumor progression) for both initial and follow-up MET-PET examinations. Therefore, the initial and follow-up data could be analyzed together as the EFS was independently calculated from each time of MET-PET.

For comparison of TNR_m and TNR_c values between groups, the Wilcoxon rank sum test was performed. A maximally selected rank statistics method was used to identify the optimal cutting points for each value and EFS. For comparison of variables in the Kaplan-Meier curves, a log-rank test was used. A P value of 0.05 was the cutoff value for statistical significance. R 4.1.2 (R Development Core Team, Vienna, Austria, http://www.R-project.org) was used for statistical analyses.

RESULTS

Patient Characteristics

A total of 26 patients were included in the study. The median age at surgery was 8.3 years (range, 3.8 to 18.8 years), and the median follow-up period was 7.5 years (range, 2.1 to 15.0 years). The mean duration of epilepsy at surgery was 9.7 months, and 65.4% of patients had less than 6 months of epilepsy duration. The tumor was located in the temporal lobe in 8 patients (30.8%) and the extratemporal location in 18 (69.2%) patients. Among the extratemporal locations, 8 (30.8%) were involved in the central lobe, within the primary motor and sensory cortex. Satellite lesions were observed in 13 (50.0%) patients, and enhancement with MRI was documented in 7 (26.9%) patients (Table 1).

The extent of resection was GTR in 10 (37.0%), NTR in 6 (22.2%), and STR in 11 patients (40.7%). Seven patients had clinical events after initial surgery: 5 patients experienced seizure recurrence, 1 patient had tumor progression, and 1 patient had tumor bleeding. One patient had seizure recurrence after initial GTR and underwent reoperation for FCD type 1 near the initial tumor site (Table 2). Seizure outcome 1 year postoperative was Engel class I in 76.9% of patients and Engel class II to IV in 6 (23.1%) patients.

TABLE 1. Patient Characteristics

Clinical Features	No. Cases (%) or Value
Sex (%)	
M	18 (69.2)
F	8 (30.8)
Median age, y	
At epilepsy onset	7.8 (2.2–18.4)
At surgery	8.3 (3.8–18.8)
Median follow-up period, y	7.5 (2.1–15.0)
Duration of epilepsy at surgery	
Mean ± SD, mo	9.7 ± 1.6
<6 mo (%)	17 (65.4)
<2 mo (%)	7 (26.9)
Tumor location (%)	
Temporal	8 (30.8)
Frontal, parietal, occipital	10 (38.4)
Central	8 (30.8)
Presence of satellite lesion (%)	
Present	13 (50.0)
Absent	13 (50.0)
Enhancement on MRI (%)	
Enhancement	7 (26.9)
No enhancement	19 (73.1)
Engel classification at first year (%)	
I	20 (76.9)
II–IV	6 (23.1)
Engel classification at the last follow-up (%)	
I	23 (88.5)
II–IV	3 (11.5)

M, male; F, female; SD, standard deviation.

TABLE 2. Clinical Information and Visual, Quantitative 27 MET-PET Data of 26 Patients

Patient No.	Sex	Age at Surgery	TNR_m	TNRc	Visual Grade	Clinical Activity at PET	Extent of Resection	Ki-67 Index	Event Occurrence
1	M	12	1.62*	1.46*	Low*	Quiescent*	STR	1%	—
2	F	8	2.10*	2.14*	High*	Active*	GTR†	1.6%	—
3	M	6	1.64*	1.62*	High*	Active*	STR†	<1%	Seizure recurrence*
4	M	13	4.23*	2.83*	High*	Active*	GTR†	<1%	—
5	F	5	1.78	1.79	High	Active	GTR	18.16%	—
6	M	17	1.13	1.15	Moderate	Quiescent	NTR	1.92%	Tumor progression
7	M	6	1.30*	1.25*	Moderate*	Quiescent*	STR	<1%	—
8	F	10	1.54	1.47	Moderate	Quiescent	NTR	1.3%	Seizure recurrence
			2.01*	1.85*	High*	Active*	NTR†	2.1%	Tumor progression*
9	M	3	2.07	2.13	High	Active	GTR	26.29%	—
10	M	10	1.29	1.42	Moderate	Active	STR	<1%	—
11	M	5	1.46	1.49	Moderate	Active	STR	1.2%	—
12	M	10	1.26	1.27	Low	Quiescent	GTR	<1%	Seizure recurrence
13	F	6	1.27	1.09	Low	Quiescent	NTR	3.8%	Tumor bleeding
14	M	8	1.61	1.44	Low	Quiescent	GTR	—	—
15	M	13	1.67	1.23	Low	Quiescent	GTR	<1%	—
16	F	7	1.93	1.69	High	Active	STR	<1%	Seizure recurrence
17	M	5	1.87	1.82	Moderate	Quiescent	NTR	1.1%	—
18	F	10	1.85	1.71	Moderate	Quiescent	STR	1%	—
19	M	4	2.72*	2.38*	High*	Active*	NTR†	6.4%	Tumor progression*
20	M	14	2.91	2.56	High	Quiescent	GTR	—	—
21	M	18	1.24	1.33	Moderate	Quiescent	GTR	—	—
22	F	9	1.53	1.41	Low	Quiescent	GTR	<1%	—
23	M	5	2.77	2.21	High	Active	STR	2%	Seizure recurrence
24	M	10	2.28	2.25	Low	Quiescent	GTR	<1%	—
25	M	7	3.21	2.90	High	Active	STR	2.6%	Seizure recurrence
26	F	7	1.73	1.71	Moderate	Quiescent	GTR	<1%	—

*Indicates follow-up data after initial operation.
†Indicates second operation.
M, male; F, female.

Of 6 patients who developed seizure recurrence during follow-up, 5 patients resulted in Engel class I outcome after reoperation, and 1 patient had Engel class II outcome. Three patients were Engel class II to IV at the last follow-up, 1 mentioned previously, and the other 2 with Engel class III did not have reoperation. The Ki-67 count, a proliferative index, was low in the majority of cases, but 2 cases (patients 5 and 9) showed Ki-67 indices of 18.2% and 26.3%, respectively.

Patterns of MET-PET and Its Correlation With Clinical Activity at the Time of PET Examination

A total of 27 MET-PET examinations, 20 initial MET-PET and 7 follow-up MET-PET examinations, were included. One patient (patient 8) had both initial and follow-up MET-PET data. Initial PET data of DNETs showed low-moderate uptake in 14 (70.0%) and high uptake in 6 (30.0%) by visual grading. Follow-up PET showed high uptake in 5 (71.4%) of 7 examinations.

Comparison of TNR_m and TNR_c according to the clinical activity of the tumor at the time of PET was performed (Fig. 1). The TNR_m values for the quiescent group (1.65 ± 0.46) and active group (2.27 ± 0.84) showed a significant difference ($P = 0.02$), and the TNR_c values for the quiescent group (1.54 ± 0.41) and active group (2.04 ± 0.49) also presented statistical significance ($P = 0.01$).

MET-PET and Anticipation of Future Clinical Events

Among 6 patients who showed high uptake on initial MET-PET, 3 patients with GTR were event-free during follow-up. The other 3 patients with STR of the tumor underwent reoperation due to seizure recurrence (Fig. 2). On follow-up MET-PET, 5 patients showed high uptake and 2 patients showed low-moderate uptake. Of 5 patients with high uptake on follow-up MET-PET, 2 patients with GTR were event-free and the other 3 patients presented events with incomplete tumor resection (Table 2, Fig. 3). The MET uptake correlates with the change of clinical activity of DNETs (Fig. 4). The MET uptake showed globular-shaped pattern in DNETs with high proliferative indices (Fig. 5).

The log-rank test for EFS was performed to compare groups by visual grading. Analysis of 27 MET-PET examinations did not show a significant difference in EFS between the low-moderate and high uptake groups ($P = 0.18$). When 15 MET-PET examinations were included for survival analysis excluding patients with GTR, high MET-PET uptake was significantly related to event occurrence ($P < 0.01$). Using the maximally selected rank statistics method to identify cutoff values for EFS, the estimated cutoff for TNR_m was 1.90, and TNR_c was 1.85. In the log-rank test using these cutoff values, the high TNR_m and TNR_c groups showed significantly worse clinical prognoses (Fig. 6).

DISCUSSION

DNETs are low-grade glioneuronal tumors with strong epileptogenic potential. Seizure control is important for patients with this tumor.[6,20] It was believed that DNETs grow indolently, and that a favorable outcome could be achieved even with incomplete

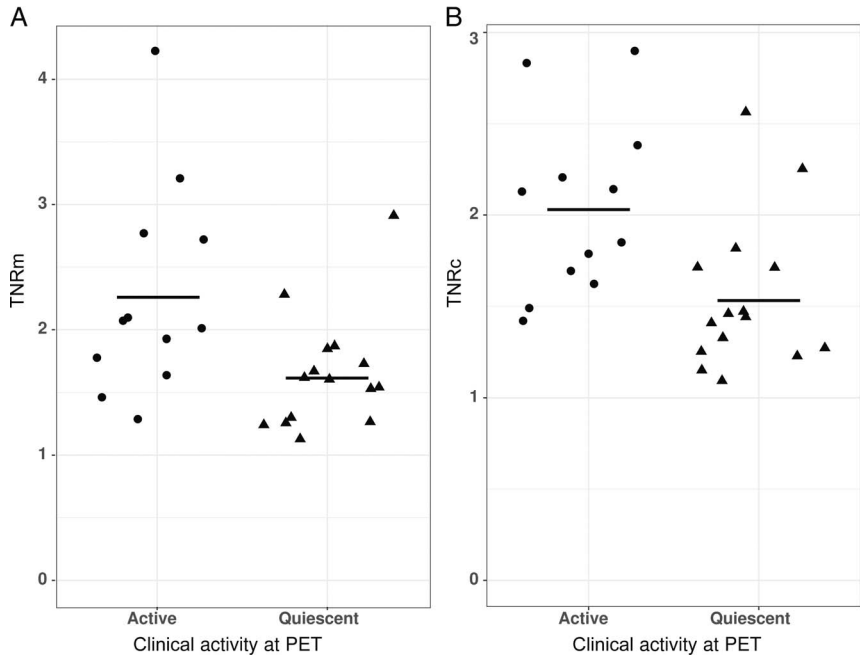

FIGURE 1. MET-PET uptake correlates well with the clinical behavior of DNETs at the time of PET examination. With a total of 27 MET-PET examinations, comparison of quiescent and active group showed a significant difference for both TNR_m ($P = 0.02$) (**A**) and TNR_c ($P = 0.01$) (**B**). The horizontal bar indicated the mean value of each group.

removal of the tumor.[1,2] However, subsequent studies with long-term follow-up data reported a higher rate of seizure and tumor recurrence.[21,22] Tumor progression and/or clinical seizure recurrence develop in at least 20% of patients with DNETs.[9,23] Daghistani et al[11] reported that reoperations were required in 11 of 51 patients (21.6%) and 6 of 18 patients with STR (33.3%), resulting in tumor progression, and recommended close observation for patients with residual tumors.

Our results show that MET-PET correlates with the biologic behavior of the tumor. TNR_m and TNR_c values were significantly

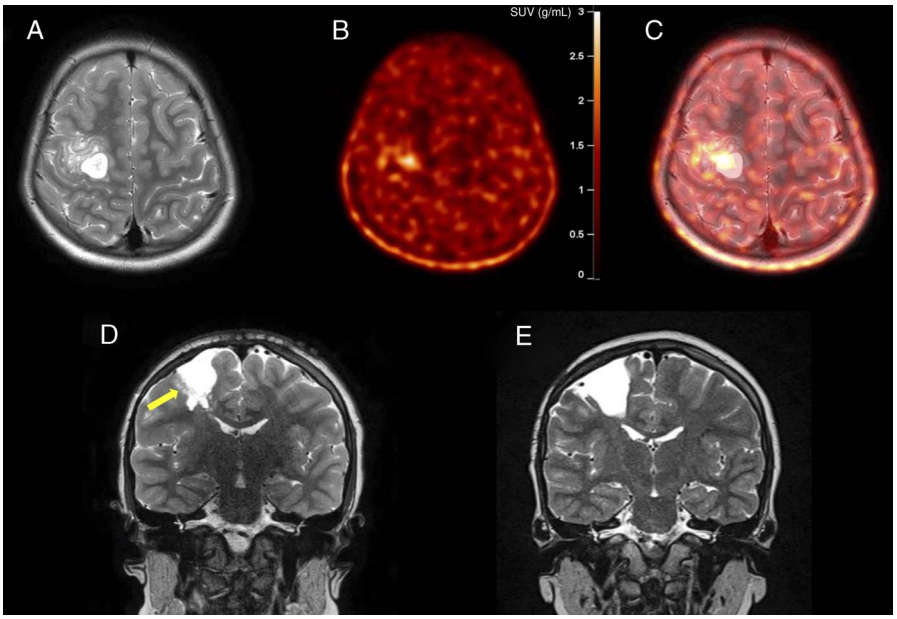

FIGURE 2. A case with a tumor exhibiting high uptake on initial MET-PET and event occurrence after operation. The MRI scans of a 7-year-old boy showed a T2-hyperintense lesion with a bubble-like appearance and satellite lesions in the right central lobe (**A**). The lesion exhibited high uptake on initial MET-PET (**B**) and fusion PET-MRI scans (**C**). STR of the tumor was confirmed by postoperative MRI (arrow) (**D**); 1.7 years after the initial operation, the seizure recurred on tapering medication and was aggravated thereafter. Reoperation was performed, and GTR of the residual tumor was confirmed with postoperative MRI (**E**). The patient was event-free at the 2.0 year follow-up with an Engel class I seizure outcome.

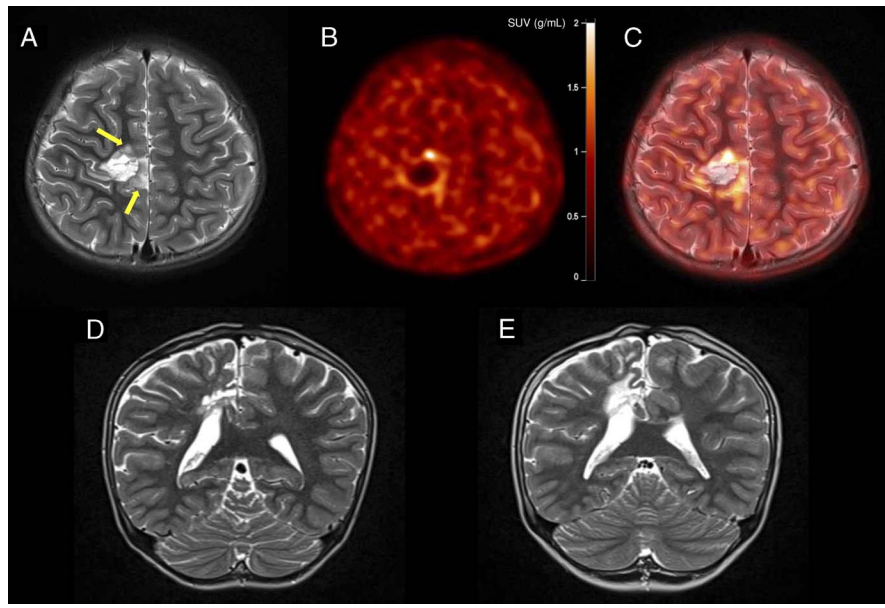

FIGURE 3. A case with a residual tumor exhibiting high uptake on follow-up MET-PET and event occurrence after reoperation. MRI scans of a 4-year-old boy who underwent tumorectomy for a DNET involving the adjacent cortex in the right central lobe and the posterior cingulum. The tumor was subtotally resected, and seizures recurred at 1.0 years postoperatively. On follow-up MRI and MET-PET images (**A**–**C**), the residual tumor was confirmed to have increased MET uptake at the margin of the tumorectomy site (arrows). The patient underwent reoperation, and NTR of the tumor was observed on postoperative MRI (**D**). Tumor progression was confirmed on 4.3 years follow-up MRI (**E**), and the patient is still on clinical surveillance because of the absence of symptoms.

different according to the clinical activity of the tumor. High MET-PET uptake was significantly correlated with worse EFS. Partial volume effect in small tumors may have been a cause of such correlation between the uptake and the prognosis. However, there was no definite correlation between the tumor volume and the uptake, which suggests that the uptake is a more significant factor

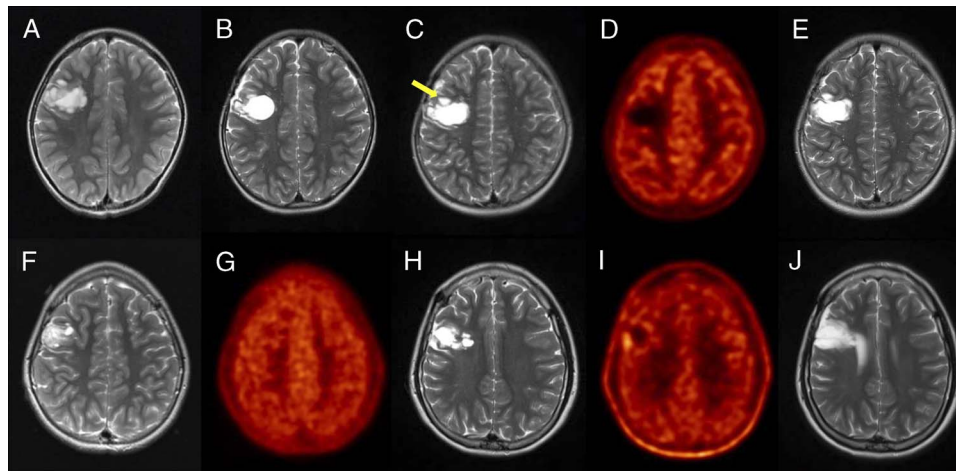

FIGURE 4. The clinical activity of DNETs may change and MET uptake correlates with the phase of the tumor. The first patient, a 6-year-old boy, with a right central lobe DNET (**A**) had STR of the tumor, which was confirmed on postoperative MRI (**B**). Follow-up MRI at 2.2 years after surgery demonstrated progression of the residual tumor with increased extent of the high signal intensity lesion on T2-weighted MR images (arrow) (**C**). MET-PET was performed for further evaluation, and tumor uptake was low (**D**). On the 4.9 years follow-up MRI, there was no evidence of tumor progression (**E**). The second patient, a 10-year-old girl, was diagnosed with a right central lobe DNET on MRI (**F**), and initial MET-PET showed moderate tumor uptake (**G**). After NTR of the tumor, seizure recurred at postoperative 3.5 years. Follow-up MRI (**H**) and MET-PET (**I**) images obtained after seizure occurrence revealed a progressed tumor with high MET uptake in a rim-like pattern. The patient underwent reoperation and NTR of the tumor was performed, but the 6.3 years follow-up MRI after reoperation showed tumor progression (**J**).

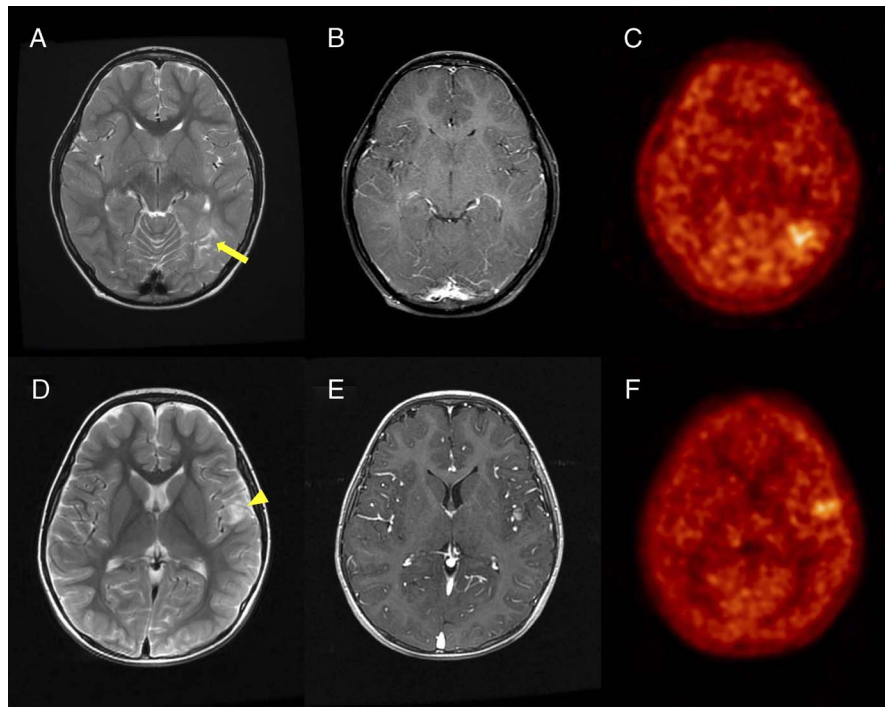

FIGURE 5. Different shape of MET uptake in DNETs with increased proliferative activity. MRI and PET images of a 5-year-old girl and a 3-year-old boy. The first patient had an ill-defined T2-hyperintensity lesion with no definite contrast enhancement in the left temporo-occipital lobe (arrow) (**A** and **B**). The lesion demonstrated globular-shaped uptake on MET-PET images (**C**). The patient underwent GTR of the tumor, which exhibited a Ki-67 count of 18.2% in the pathologic examination. The other patient had a T2-hyperintensity lesion with subtle contrast enhancement in the left temporal lobe (arrowhead) (**D**–**E**). The lesion demonstrated globular-shaped uptake on MET-PET images (**F**). The patient underwent GTR of the tumor, which exhibited a Ki-67 count of 26.3%. Both patients were event-free at the last follow-up.

for the outcome than the tumor volume. The extent of resection in the initial operations in our study was GTR (10; 37.0%) and incomplete tumor resection (16; 63.0%). The rate of GTR seems to be low compared with previous reports, with GTR rates approximately 70%.[4] This finding could be explained by the definition of GTR in our study, in which the satellite lesions must also be removed. The definition of GTR in other studies is similar to the definition of NTR in our study because most surgeons do not remove deep-seated satellite lesions. The rates of GTR and NTR together are 59.2% in our study, which is comparable to those of previous reports. In addition, central lobe location also contributed to a low GTR rate since only 1 patient had GTR of 8 patients with central lobe location. MRI enhancement has been suggested to correlate with tumor recurrence or aggressive behavior; however, no statistical significance was observed in our study.[11,24]

Quantitative analysis of our study tends to present higher values compared with earlier works that addressed MET-PET uptake of DNETs.[17,18] Our measurement and calculation method of TNR_m and TNR_c were performed to enhance the contrast of baseline and tumor uptake values. MET-PET uptake is higher in cortices than in subcortical areas, and TNR_m was calculated with baseline homotopic mirror area ROIs, which also included subcortical areas. For this reason, TNR_m showed higher values, especially in some patients, than TNR_c (Table 2). Another explanation for these higher values is that we calculated the mean uptake value of baseline ROIs (M_{mean} and C_{mean}) to increase the contrast of values. Previous studies have used the maximum uptake value of baseline ROIs as the denominator.[17,18] Even in those studies, the results show several cases of DNETs with increased MET-PET uptake.

The composite surgical outcome was used because tumor progression infrequently occurs in DNETs and the true incidence of tumor progression is not yet known.[3,9,24] Our data also demonstrated only 2 cases of tumor progression, whereas other DNETs showed insignificant changes in the tumor. Instead, 6 of 10 events were seizure recurrence without noticeable volume changes of residual tumors. Therefore, high MET-PET is closely related to seizure recurrence if a residual tumor is present. Hemorrhage of residual tumor or malignant transformation has been rarely reported but should be included in the clinical event due to their burden; 1 patient presented with tumor bleeding in our data.[25,26]

There may be a question of whether all remnant seizures after surgery should be considered as clinical events of DNETs. Thus, we included patients in whom seizures recurred or showed aggravation despite antiseizure medications, and patients with seizures controlled at Engel class I, II were excluded. The timing of surgical intervention was early in our cohort for both initial and recurrent cases, as previous studies have stated that lesion-associated epilepsy tends to be more resistant to medications and that a longer duration of seizure results in poorer seizure control outcomes and more deficits.[27,28] Our data presented a first-year seizure-free outcome of 80.8%, and all patients became seizure-free after reoperation, except for 1 patient who continued to have seizures after treatment, though far less severe (Engel class II outcome).

In our study, the eccentric characters of DNETs were observed by MET-PET uptake. From the MET-PET uptake findings in Figure 4, we suggest that DNETs do not have constant biologic behavior and demonstrate an active and quiescent phase. In this way, the behavior of DNETs, for example, late progression of a stable

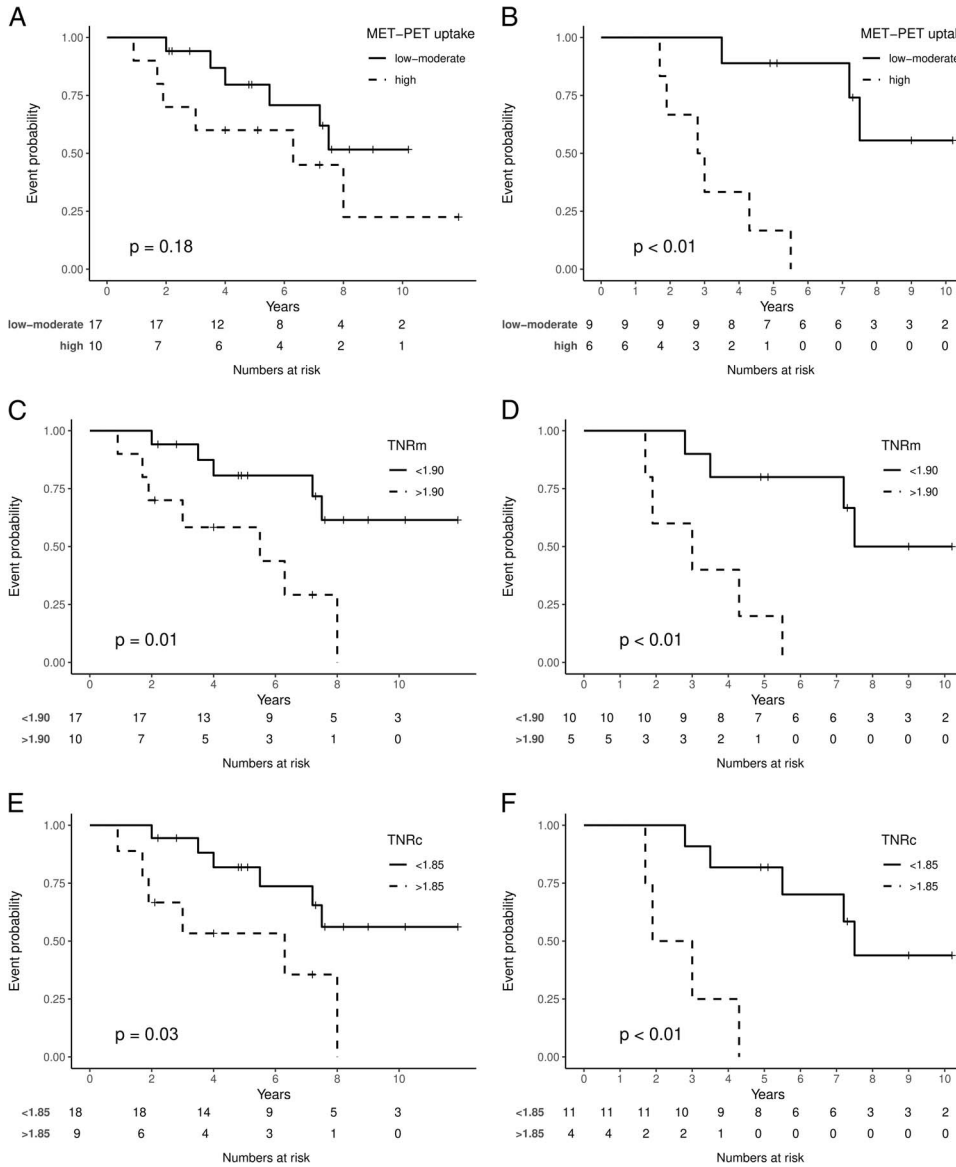

FIGURE 6. High MET-PET uptake is significantly related to event occurrence. In relation to the visual grade, there was no significant difference in EFS among the 27 MET-PET examinations (**A**), whereas exclusion of patients with GTR 15 MET-PET examinations revealed a significant difference between the high uptake and the low-moderate uptake group (**B**). There was a significant difference in EFS between the $TNR_m \geq 1.90$ and $TNR_m < 1.90$ groups. Both in total (**C**) and in 15 MET-PET examinations (**D**). The $TNR_c \geq 1.85$ and $TNR_c < 1.85$ groups also presented differences in EFS in both total (**E**) and 15 MET-PET examinations (**F**).

residual lesion after years of dormancy, may be explained. Interestingly, the shape of the MET-PET uptake pattern showed difference in DNETs with high Ki-67 indices, as shown in Figure 5. In contrast, tumors with low Ki-67 and seizure presentation demonstrated high uptake along the periphery of the tumor. This finding coincides with prior studies showing that the pathophysiology of lesional epilepsy is related to changes in the adjacent cortex and that amino acid receptors are more strongly dispersed in the tumor margins of DNETs.[29,30]

There are some limitations of this study owing to its retrospective nature. First, due to the small number of patient groups, the statistical strength of our results was lacking. Nevertheless, we observed a clear significant difference between groups. Another limitation is that the analysis of composite events as outcomes may lead to bias of the results because the incidence of clinical events and tumor progression differs. Further clinical data of MET-PET with DNET management must be accumulated from subsequent studies.

CONCLUSIONS

MET-PET uptake correlates well with the clinical behavior of DNETs at the time of PET examination. Moreover, MET-PET is helpful for predicting the clinical outcome of tumors. We propose that preoperative and follow-up evaluation with MET-PET in DNETs is useful for investigating the eccentric characteristics of the tumor and their management. Furthermore, efforts to achieve GTR should be made for DNETs with high MET-PET uptake.

REFERENCES

1. Daumas-Duport C, Scheithauer BW, Chodkiewicz J-P, et al. Dysembryoplastic neuroepithelial tumor: a surgically curable tumor of young patients with intractable partial seizures: report of thirty-nine cases. *Neurosurgery*. 1988;23: 545–556.
2. Daumas-Duport C, Varlet P, Bacha S, et al. Dysembryoplastic neuroepithelial tumors: nonspecific histological forms—a study of 40 cases. *J Neurooncol*. 1999;41:267–280.
3. Maher CO, White JB, Scheithauer BW, et al. Recurrence of dysembryoplastic neuroepithelial tumor following resection. *Pediatr Neurosurg*. 2008;44: 333–336.
4. Bonney PA, Boettcher LB, Conner AK, et al. Review of seizure outcomes after surgical resection of dysembryoplastic neuroepithelial tumors. *J Neurooncol*. 2016;126:1–10.
5. Rivera B, Gayden T, Carrot-Zhang J, et al. Germline and somatic FGFR1 abnormalities in dysembryoplastic neuroepithelial tumors. *Acta Neuropathol*. 2016;131:847–863.
6. Luyken C, Blümcke I, Fimmers R, et al. The spectrum of long-term epilepsy–associated tumors: long-term seizure and tumor outcome and neurosurgical aspects. *Epilepsia*. 2003;44:822–830.
7. Ranger A, Diosy D. Seizures in children with dysembryoplastic neuroepithelial tumors of the brain—a review of surgical outcomes across several studies. *Childs Nerv Syst*. 2015;31:847–855.
8. Chan CH, Bittar RG, Davis GA, et al. Long-term seizure outcome following surgery for dysembryoplastic neuroepithelial tumor. *J Neurosurg*. 2006;104: 62–69.
9. Nolan MA, Sakuta R, Chuang N, et al. Dysembryoplastic neuroepithelial tumors in childhood: long-term outcome and prognostic features. *Neurology*. 2004;62:2270–2276.
10. Stokland T, Liu J-F, Ironside JW, et al. A multivariate analysis of factors determining tumor progression in childhood low-grade glioma: a population-based cohort study (CCLG CNS9702). *Neuro Oncol*. 2010; 12:1257–1268.
11. Daghistani R, Miller E, Kulkarni AV, et al. Atypical characteristics and behavior of dysembryoplastic neuroepithelial tumors. *Neuroradiology*. 2013; 55:217–224.
12. Chassoux F, Rodrigo S, Mellerio C, et al. Dysembryoplastic neuroepithelial tumors: an MRI-based scheme for epilepsy surgery. *Neurology*. 2012;79: 1699–1707.
13. Yang J, Kim S-K, Kim KJ, et al. Satellite lesions of DNET: implications for seizure and tumor control after resection. *J Neurooncol*. 2019;143:437–445.
14. Chung J-K, Kim YK, Kim S-K, et al. Usefulness of ^{11}C-methionine PET in the evaluation of brain lesions that are hypo- or isometabolic on ^{18}F-FDG PET. *Eur J Nucl Med Mol Imaging*. 2002;29:176–182.
15. Kato T, Shinoda J, Oka N, et al. Analysis of ^{11}C-methionine uptake in low-grade gliomas and correlation with proliferative activity. *Am J Neuroradiol*. 2008;29:1867–1871.
16. Phi JH, Paeng JC, Lee HS, et al. Evaluation of focal cortical dysplasia and mixed neuronal and glial tumors in pediatric epilepsy patients using ^{18}F-FDG and ^{11}C-methionine pet. *J Nucl Med*. 2010;51:728–734.
17. Rosenberg DS, Demarquay G, Jouvet A, et al. [^{11}C]-Methionine PET: dysembryoplastic neuroepithelial tumours compared with other epileptogenic brain neoplasms. *J Neurol Neurosurg Psychiatry*. 2005;76:1686–1692.
18. Rheims S, Rubi S, Bouvard S, et al. Accuracy of distinguishing between dysembryoplastic neuroepithelial tumors and other epileptogenic brain neoplasms with [^{11}C] methionine PET. *Neuro Oncol*. 2014;16:1417–1426.
19. Engel J Jr. Update on surgical treatment of the epilepsies. Summary of the Second International Palm Desert Conference on the Surgical Treatment of the Epilepsies. (1992). *Neurology*. 1993;43:1612–1617.
20. Thom M, Blümcke I, Aronica E. Long-term epilepsy-associated tumors. *Brain Pathol*. 2012;22:350–379.
21. Lee DY, Chung CK, Hwang YS, et al. Dysembryoplastic neuroepithelial tumor: radiological findings (including PET, SPECT, and MRS) and surgical strategy. *J Neurooncol*. 2000;47:167–174.
22. Stanescu Cosson R, Varlet P, Beuvon F, et al. Dysembryoplastic neuroepithelial tumors: CT, MR findings and imaging follow-up: a study of 53 cases. *J Neuroradiol*. 2001;28:230–240.
23. Bilginer B, Yalnızoglu D, Soylemezoglu F, et al. Surgery for epilepsy in children with dysembryoplastic neuroepithelial tumor: clinical spectrum, seizure outcome, neuroradiology, and pathology. *Childs Nerv Syst*. 2009;25: 485–491.
24. Ray WZ, Blackburn SL, Casavilca-Zambrano S, et al. Clinicopathologic features of recurrent dysembryoplastic neuroepithelial tumor and rare malignant transformation: a report of 5 cases and review of the literature. *J Neurooncol*. 2009;94:283–292.
25. Campos AR, Clusmann H, von Lehe M, et al. Simple and complex dysembryoplastic neuroepithelial tumors (DNT) variants: clinical profile, MRI, and histopathology. *Neuroradiology*. 2009;51:433–433.
26. Heiland DH, Staszewski O, Hirsch M, et al. Malignant transformation of a dysembryoplastic neuroepithelial tumor (DNET) characterized by genome-wide methylation analysis. *J Neuropathol Exp Neurol*. 2016;75: 358–365.
27. Englot DJ, Berger MS, Barbaro NM, et al. Factors associated with seizure freedom in the surgical resection of glioneuronal tumors. *Epilepsia*. 2012; 53:51–57.
28. Radhakrishnan A, Abraham M, Vilanilam G, et al. Surgery for "long-term epilepsy associated tumors (LEATs)": seizure outcome and its predictors. *Clin Neurol Neurosurg*. 2016;141:98–105.
29. Shamji MF, Fric-Shamji EC, Benoit BG. Brain tumors and epilepsy: pathophysiology of peritumoral changes. *Neurosurg Rev*. 2009;32:275–284; discussion 284–276.
30. Adamek D, Korzeniowska A, Morga R, et al. Dysembryoplastic neuroepithelial tumour (DNT). Is the mechanism of seizures related to glutamate? An immunohistochemical study. *Folia Neuropathol*. 2001;39: 111–117.